

Intracorneal continuous ring implantation for keratoconus: One-year follow-up

Albert Daxer, MD, PhD, Haifa Mahmoud, MD, Rengaswamy Srinivasan Venkateswaran, OD

PURPOSE: To evaluate intracorneal continuous ring (ICCR) implantation for the treatment of keratoconus.

SETTING: Eye specialist centers, Europe and Middle East.

METHOD: This study assessed the results of implantation of a MyoRing ICCR in 15 eyes with keratoconus. Outcome measures included uncorrected distance visual acuity (UDVA), corrected distance visual acuity (CDVA) (spectacle correction), refraction, complications, and side effects. Postoperative follow-up was up to 1 year.

RESULTS: The study evaluated 15 eyes of 11 patients (8 men, 3 women) with a mean age of 35 years \pm 12 (SD) (range 22 to 60 years). Preoperatively, the mean central corneal thickness was 435 ± 41 μ m (range from 350 to 485 μ m) and the mean keratometry (K) readings, 48.96 ± 3.4 diopters (D) (range 43.75 to 56.62 D). Postoperatively, there was a statistically significant improvement in the UDVA, CDVA, K readings, manifest spherical and cylindrical refractive errors, and spherical equivalent ($P < .05$). The mean UDVA improved by almost 10 lines, from 0.07 (1.24 ± 0.35 logMAR) to 0.56 (0.27 ± 0.17 logMAR), and the mean CDVA improved by almost 3 lines, from 0.42 (0.40 ± 0.17 logMAR) to 0.77 (0.12 ± 0.10 logMAR). The mean K reading decreased by 5.76 D, from 48.96 D to 43.20 D. No serious intraoperative complications occurred. Side effects included glare and night-vision problems.

CONCLUSIONS: Treatment of keratoconus with ICCR implantation significantly improved visual function. The nomogram requires grading the disease using the K readings only. The UDVA and CDVA also improved during the first postoperative year.

Financial Disclosure: Drs. Mahmoud and Venkateswaran have no financial or proprietary interest in any material or method mentioned. Additional disclosure is found in the footnotes.

J Cataract Refract Surg 2010; 36:1296–1302 © 2010 ASCRS and ESCRS

Keratoconus is a corneal disease characterized by progressive thinning and ectasia of the cornea.¹ Changes in the collagen matrix may be responsible for the weakening of the keratoconic cornea.² Implantation of intrastromal corneal ring segments (ICRS) in a circular corneal tunnel can improve the visual function and may, therefore, reduce the rate of keratoplasty.³ Implantation of an intracorneal continuous ring (ICCR) has been shown to be effective in single cases of high myopia and keratoconus.^{4,5} The purpose of this study was to evaluate the refractive results of implantation of an intracorneal continuous ring (ICCR) to treat keratoconus with follow-up times up to 1 year.

PATIENTS AND METHOD

This study evaluated eyes with keratoconus that were treated by implantation of a MyoRing ICCR (Dioptex

GmbH) in a corneal pocket created using a PocketMaker microkeratome (Dioptex GmbH), as described elsewhere.^{4,5} The aim was to center the ICCR at the pupil. Table 1 shows the nomogram used to select the ICCR.

The inclusion criteria were no corneal scar, no history of corneal surgery, a minimum corneal thickness 350 μ m, an uncorrected distance visual acuity (UDVA) not better than 0.25, and a keratometry (K) reading greater than 42.00 diopters (D) using the following formula: $K = (K1 + K2)/2$. Eyes in which the ICCR position required adjustment to correct decentration within the first month were excluded from the statistical analysis; the repositioning technique has been described.⁵ Eyes that had corneal collagen crosslinking (CXL) in addition to ICCR implantation⁶ were also excluded from the statistical evaluation. The remaining eyes were included in the statistical analysis of the pure effect of the ICCR in the corneal pocket over time, with postoperative visits at 1, 3, 6, and 12 months.

Keratometry readings were performed using the Keratron topography system (Optikon 2000 S.p.A.) and the Pentacam Scheimpflug imaging system (Oculus GmbH). Corneal

Table 1. Current nomogram.

K Value	ICCR Dimension	
	Diameter (mm)	Thickness (μm)
<49.00 D	5	240
49.00 to 55.00 D	5	280
>55.00 D	5	280 + CXL

CXL = additional crosslinking; ICCR = intracorneal continuous ring; K = keratometry

thickness was measured by ultrasound pachymetry (Pocket II Pachymeter Echograph, Quantel Medical).

In addition to keratometry, outcome measures included the UDVA, corrected distance visual acuity (CDVA), K readings, spherical and cylindrical components of the manifest refraction, and spherical equivalent (SE). Lines of improvement in acuity were calculated in logarithmic scales according to logMAR notation. In all cases, the CDVA is reported with spectacle correction.

If not otherwise stated, statistical data are presented as means \pm SD and the K reading is from the 3.0 mm zone. The preoperative and 1-year postoperative data were statistically compared using a 2-tailed paired *t* test in GraphPad Prism 4 software for Macintosh (version 4.0c, GraphPad Software, Inc.). The changes in data were considered statistically significant when the *P* value was less than 0.05. The UDVA and CDVA were obtained in decimal scaling and transformed into logMAR for statistical analysis.

RESULTS

Of the 21 eyes that had ICCR implantation in this series, 2 required ICCR repositioning and 3 had ICCR implantation combined with corneal collagen cross-linking (CXL); per the study protocol, these eyes were excluded from the statistical evaluation. The

Submitted: August 14, 2009.

Final revision submitted: January 17, 2010.

Accepted: March 9, 2010.

From the Eye Center (Daxer), Linz–Ybbs, and the Department of Ophthalmology (Daxer), Medical University of Innsbruck, Innsbruck, Austria; Dr. Haifa Mahmoud Eye Specialist Center (Mahmoud, Venkateswaran), Manama, Kingdom of Bahrain.

Additional financial disclosure: Dr. Daxer is a founder of DiopTex GmbH.

Presented in part at the XXVII Congress of the European Society of Cataract & Refractive Surgeons, Barcelona, Spain, September 2009; the 10th International Meeting of the Middle East Africa Council of Ophthalmology, Bahrain, March 2009; and the ASCRS Symposium on Cataract, IOL and Refractive Surgery, San Francisco, California, USA, April 2009.

Corresponding author: Albert Daxer, MD, PhD, Stauwerkstrasse 1, 3370 Ybbs, Austria. E-mail: daxer@gutsehen.at.

Table 2. Preoperative visual and refractive data.

Parameter	Result
UDVA	
Mean logMAR \pm SD	1.24 \pm 0.35
Mean decimal	0.07
CDVA*	
Mean logMAR \pm SD	0.40 \pm 0.17
Mean decimal	0.42
Mean sphere (D) \pm SD	-5.13 \pm 4.34
Mean cylinder (D) \pm SD	-3.50 \pm 1.20
Mean SE (D) \pm SD	-6.27 \pm 5.20
Mean K value (D) \pm SD	48.96 \pm 3.42

CDVA = corrected distance visual acuity; K = keratometry; SE = spherical equivalent; UDVA = uncorrected distance visual acuity
*Spectacle corrected

remaining 15 eyes of 11 patients (8 men, 3 women) were evaluated. The mean age of the patients was 35 years \pm 12 (SD) (range 22 to 60 years). Table 2 shows the preoperative refractive data. The mean preoperative pachymetry at the thinnest point of the cornea was 435 \pm 41 μm (range 350 μm to 485 μm).

Table 3 shows the 1-year postoperative visual and refractive results. There was a statistically significant improvement in all parameters from preoperatively to postoperatively as follows: logMAR UDVA, *P* < .0001; logMAR CDVA, *P* < .0001; K reading, *P* = .0009; sphere, *P* < .0001; cylinder, *P* = .0007; SE, *P* = .0003. Figures 1 to 6 show the changes in these parameters over time. The mean UDVA improved 10 lines from preoperatively to 1 year postoperatively, the mean CDVA improved by approximately 3 lines, and the mean K improved by 5.76 D.

No eyes lost lines of CDVA or UDVA postoperatively. By 1 year, the CDVA had improved by 1 line

Table 3. Refractive data 1 year postoperatively.

Parameter	Result
UDVA	
Mean logMAR \pm SD	0.27 \pm 0.17
Mean decimal	0.56
CDVA*	
Mean logMAR \pm SD	0.12 \pm 0.10
Mean decimal	0.77
Mean sphere (D) \pm SD	0.10 \pm 3.2
Mean cylinder (D) \pm SD	-1.27 \pm 0.75
Mean SE (D) \pm SD	-0.52 \pm 3.4
Mean K value (D) \pm SD	43.20 \pm 2.99

CDVA = corrected distance visual acuity; K = keratometry; SE = spherical equivalent; UDVA = uncorrected distance visual acuity
*Spectacle corrected

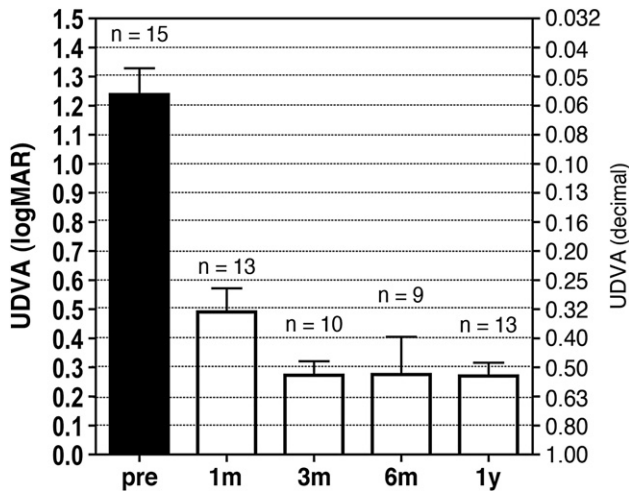


Figure 1. Mean UDVA over time. The error bars represent the SD in logMAR (UDVA = uncorrected distance visual acuity; n = number of eyes examined at the specific follow-up; pre = preoperative).

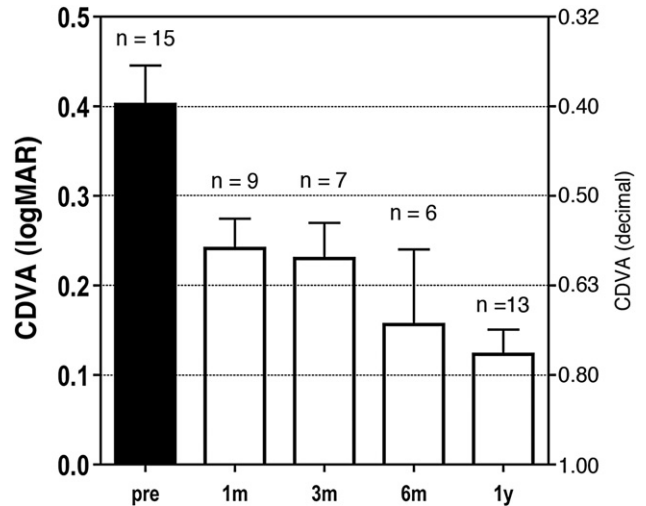


Figure 2. Mean CDVA over time. The error bars represent the SD in logMAR (CDVA = corrected distance visual acuity; n = number of eyes examined at the specific follow-up; pre = preoperative).

in 3 eyes, 2 lines in 2 eyes, 3 lines in 4 eyes, 4 lines in 2 eyes, and 5 lines in 2 eyes. The improvement in UDVA ranged from 5 to 13 lines.

Preoperatively, the UDVA was 0.1 (20/200) or worse in 14 (93%) of 15 eyes. Postoperatively, the UDVA was 0.5 (20/40) or better in 4 (31%) of 13 eyes at 1 month, 7 (70%) of 10 eyes at 3 months, 7 (78%) of 9 eyes at 6 months, and 11 (85%) of 13 eyes at 1 year. The CDVA was 0.5 or worse in 13 eyes (87%) preoperatively and 1 eye (8%) at 1 year.

There were no serious postoperative complications. Patients reported side effects more frequently in the early postoperative period than in the late postoperative period. Serious glare and night-vision problems were reported in 2 eyes. These eyes received additional pilocarpine 1% eyedrop therapy for 3 months within the first postoperative year. No ICCR was removed for side effects or complications.

Figures 7 to 12 show preoperative and postoperative comparisons in an individual case. Figures 7 and 10

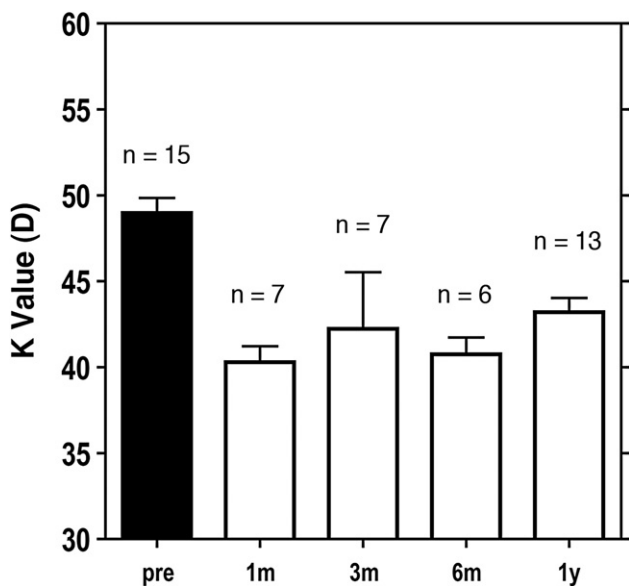


Figure 3. Mean K reading [$K = (K1 + K2)/2$] over time. The error bars represent the SD (K = keratometry; n = number of eyes examined at the specific follow-up; pre = preoperative).

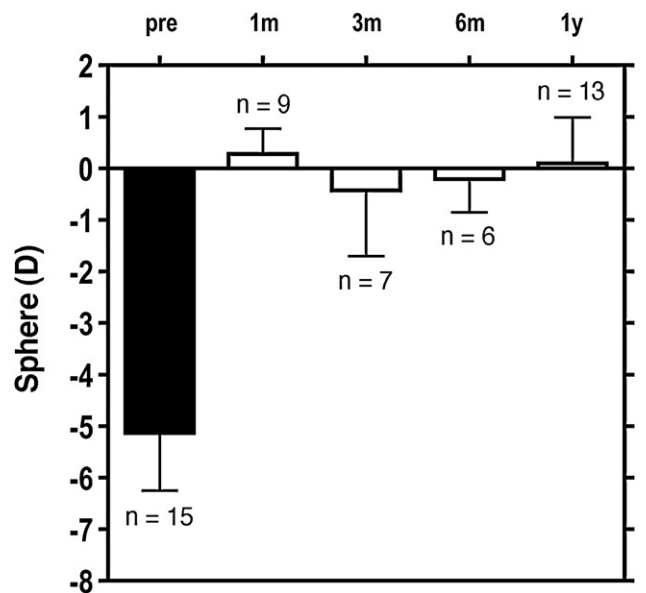


Figure 4. Mean spherical component of the refractive error over time. The error bars represent the SD (n = number of eyes examined at the specific follow-up; pre = preoperative).

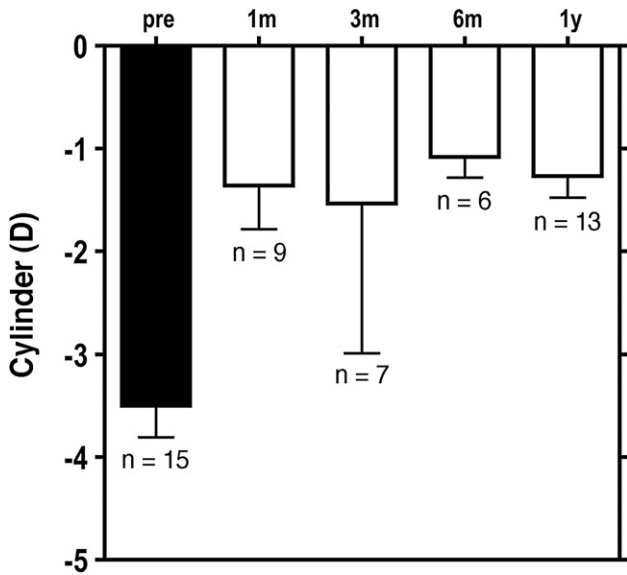


Figure 5. Mean cylindrical component of the refractive error over time. The error bars represent the SD (n = number of eyes examined at the specific follow-up; pre = preoperative).

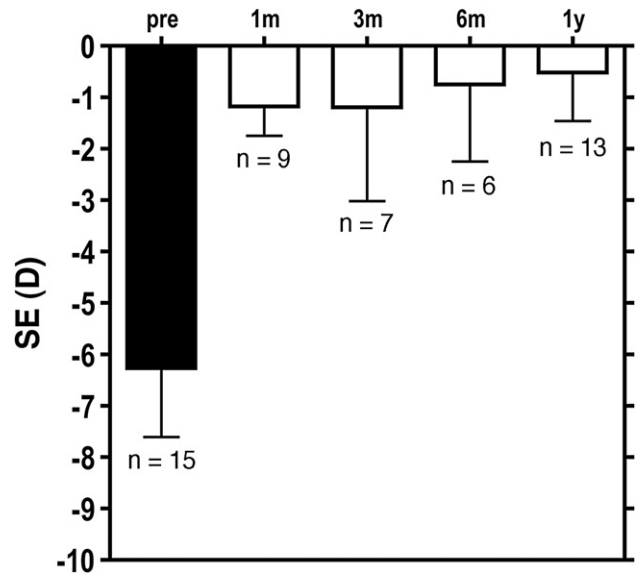


Figure 6. Mean SE over time. The error bars represent the SD (n = number of eyes examined at the specific follow-up; pre = preoperative; SE = spherical equivalent).

show the preoperative and postoperative corneal topography, respectively, in a sagittal map. Figures 8 and 11 show the preoperative and postoperative cornea topography, respectively, in a tangential map. Figures 9 and 12 show the preoperative and postoperative Scheimpflug images in the same (superior-inferior) cross-section. In this case, the preoperative K reading was 51.60 D, the UDVA was 0.05, and the CDVA was 0.30 with a manifest refraction of -3.00

-2.00×60 . One year after surgery, the K reading was 45.6 D, the UDVA was 0.6, and the CDVA was 0.7 with a manifest refraction of $+0.25 -2.25 \times 15$.

DISCUSSION

Intracorneal continuous ring implantation allows individualized treatment of keratoconus based on control of ring thickness, ring diameter, and ring centration.⁵

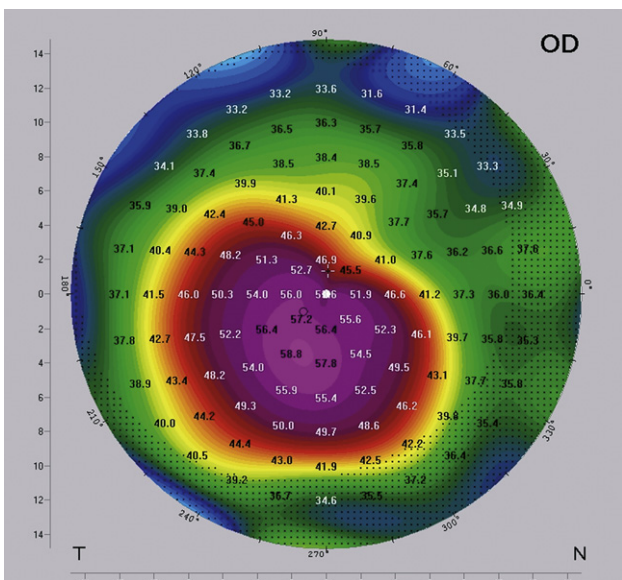


Figure 7. Preoperative topography (sagittal map) of case 14. The central cornea is irregular with the steepest point (maximum K) in the temporal-inferior quadrant.

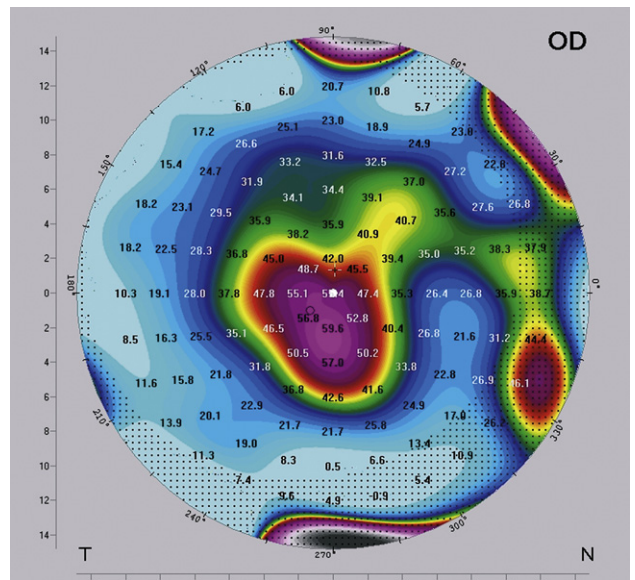


Figure 8. Preoperative topography (tangential map) of case 14. The image results from the same measurement as the image in Figure 7. The tangential map shows the local curvature.

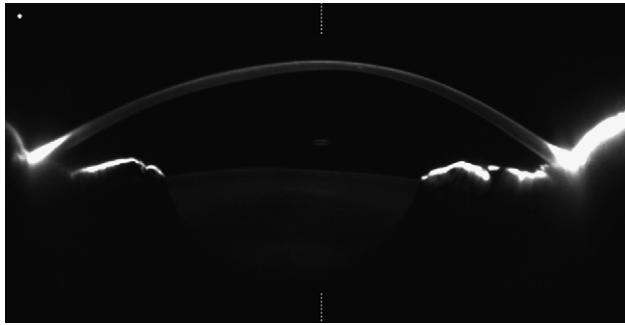


Figure 9. Preoperative Scheimpflug image of case 14. The image results from the same measurement as the images in Figures 7 and 8 and shows the cross-section along the vertical meridian. *Left:* Superior cornea. *Right:* Inferior cornea.

The ICCR can be repositioned with respect to the optical axis, which may further improve visual function. The aim is to center the ICCR on the pupil. Although the repositioning can result in significant improvement in a given case, it can also be a source of error. In some cases, the impression of centration under the surgical microscope may be wrong and the ICCR appears decentered at the slitlamp. In such cases, the ICCR may require recentration, as occurred in 2 of 17 eyes with no CXL in our study. These 2 cases were not included in the statistical analysis, which evaluated the effect of primary implantation only. The decision of whether recentration is required can be made

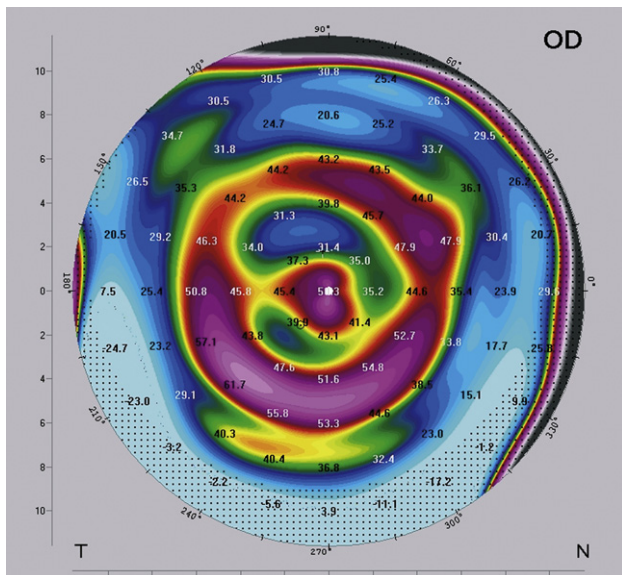


Figure 11. One-year postoperative topography (tangential map) of case 14. The image results from the same measurement as the image in Figure 10. The tangential map shows a regular central cornea with a bow-tie pattern, indicating regular corneal astigmatism and coaxial steepening surrounding the corneal center. The coaxial steepening represents the position of the ICCR, which appears to be well centered around the regular central cornea.

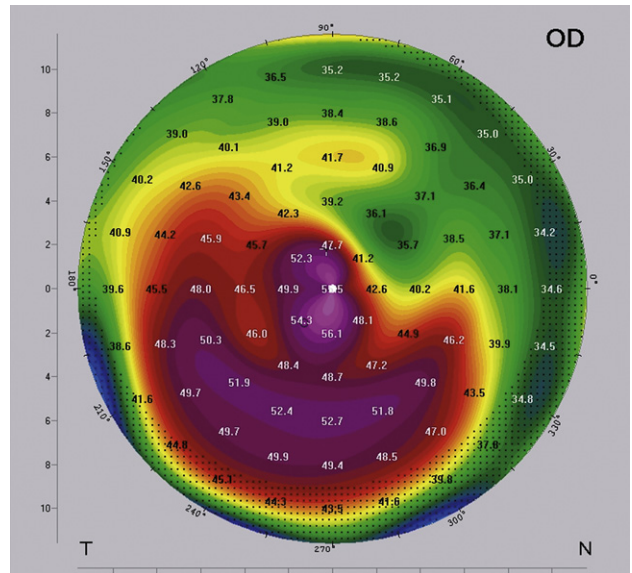


Figure 10. One-year postoperative topography (sagittal map) of case 14. The central cornea shows a bow-tie pattern, indicating fairly regular corneal astigmatism compared with the map in Figure 7.

by analyzing the tangential topographic map a few days after surgery. If the ICCR appears concentric around a fairly regular center on the tangential map (Figure 11), no intervention is required. In some cases, active surgical decentration may be necessary to achieve a sufficient refractive result. This can happen when the ICCR is well centered but the central cornea is very irregular.⁵

In the case we used as an example, the center of the cornea is fairly regular after surgery (Figures 10 and 11). This explains why the UDVA and CDVA can improve significantly even when there is no improvement in the astigmatic component of the manifest refraction. In this case, the UDVA improved by almost 11 lines and CDVA by almost 4 lines even though the

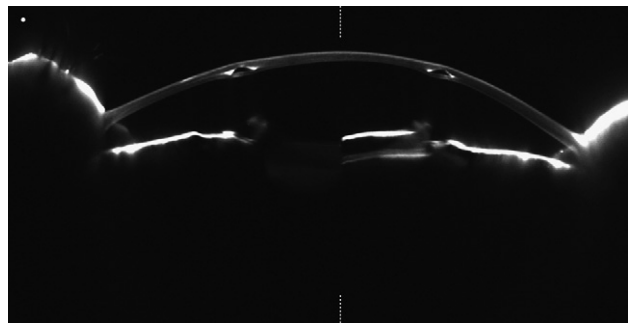


Figure 12. One-year postoperative Scheimpflug image of case 14. The image results from the same measurement as the images in Figures 7 and 8 and shows the cross-section along the vertical meridian. *Left:* Superior cornea. *Right:* Inferior cornea. The superior and inferior cross-section of the ICCR are visible as black inserts within the stroma.

absolute value of the astigmatic component remained virtually unchanged (-2.00 D preoperatively and -2.25 D postoperatively). A comparison of Figure 7 and Figure 10 shows that the cornea became more regular after surgery, resulting in a change in astigmatism from irregular (Figure 7) to regular (Figure 10), as characterized by the bow-tie pattern. The procedure to reposition the ICCR postoperatively can be completed in a short period with relative ease.⁵

During the first year after ICCR implantation, there was an improvement in UDVA and in CDVA. An explanation for this finding cannot be found in a change in refraction. The most likely explanation for the continuous improvement in visual function during the first year after surgery is adaptation to the ICCR diameter of 5.0 mm; this adaptation also decreases the incidence of side effects such as glare and night-vision problems. This explanation corresponds well with the observation that the patients subjectively reported improvement in vision over time as well as a reduction in side effects that corresponded to the improvement in vision.

Postoperative glare and night-vision problems causing patient-reported discomfort occurred in 2 of the 15 eyes. The eyes did not subjectively adapt well in the early postoperative period. They were treated with pilocarpine 1% twice daily for 3 months, after which the patients reported being happy with the results. We do not consider the 2 cases of ICCR decentration as a serious intraoperative complication that required postoperative adjustment of the ICCR position to achieve acceptable visual results.

Colin et al.³ introduced ICRS for the treatment of keratoconus. They report an improvement in mean UDVA from 0.12 to 0.30 6 months after Intacs ICRS implantation for keratoconus. The mean CDVA improved from 0.38 to 0.63 during that period. The treatment of more advanced cases of keratoconus with Intacs ICRS resulted in an improvement in the mean UDVA from 0.05 to 0.16 and in the mean CDVA from 0.50 to 0.67; the decrease in the K value was approximately 3.50 D.⁷ Using different ring segment geometries and implantation of 1 or 2 segments depending on the type of cone and severity of keratoconus provided better long-term stability.⁸⁻¹⁵ In contrast to ICRS surgery, in which segment selection requires complicated grading of the keratoconus and distinguishing between different types of cones, ICCR implantation uses a simple nomogram in which keratoconus is graded using the K readings only.

Treatment of keratoconus with keratoplasty results in more frequent and more serious complications than implantation of corneal implants.¹⁶ In a study of microkeratome-assisted lamellar keratoplasty for keratoconus, 16% of eyes had a UDVA

of 0.10 or better and 88% had a CDVA of 0.50 or better 1 year after surgery.¹⁷ The complication rates are of particular importance in more invasive keratoplasty techniques.¹⁸⁻²¹


A limitation of the present study is the use of both eyes of some patients in the analysis. The *t* test treats each sample, in this case the eye, as independent, which can falsely inflate the statistical power of the hypothesis test.

Future studies should address whether it makes sense to combine ICCR for the treatment of keratoconus with CXL to stop the progression of the disease.⁶ According to the nomogram, a particular ICCR dimension covers a wide range of K readings and, therefore, a specific severity range of the disease. Whether this means that ICCR implantation is able to "cover" a certain range of progression must also be addressed in future studies.

REFERENCES

1. Krachmer JH, Feder RS, Belin MW. Keratoconus and related noninflammatory corneal thinning disorders. *Surv Ophthalmol* 1984; 28:293-322
2. Daxer A, Fratzi P. Collagen fibril orientation in the human corneal stroma and its implication in keratoconus. *Invest Ophthalmol Vis Sci* 1997; 38:121-129. Available at: <http://www.iovs.org/cgi/reprint/38/1/121>. Accessed April 14, 2010
3. Colin J, Cochener B, Savary G, Malet F. Correcting keratoconus with intracorneal rings. *J Cataract Refract Surg* 2000; 26:1117-1122
4. Daxer A. Corneal intrastromal implantation surgery for the treatment of moderate and high myopia. *J Cataract Refract Surg* 2008; 34:194-198
5. Daxer A. Adjustable intracorneal ring in a lamellar pocket for keratoconus. *J Refract Surg* 2010; 26:217-221
6. Daxer A, Mahmoud H, Venkatesvaran RS. Corneal cross-linking and visual rehabilitation in keratoconus in one session without epithelial debridement: new technique. In press, *Cornea* 2010
7. Shetty R, Kurian M, Anand D, Mhaske P, Narayana KM, Shetty BK. Intacs in advanced keratoconus. *Cornea* 2008; 27:1022-1029
8. Alió JL, Artola A, Hassanein A, Haroun H, Galal A. One or 2 Intacs segments for the correction of keratoconus. *J Cataract Refract Surg* 2005; 31:943-953
9. Sharma M, Boxer Wachler BS. Comparison of single-segment and double-segment Intacs for keratoconus and post-LASIK ectasia. *Am J Ophthalmol* 2006; 141:891-895
10. Alió JL, Shabayek MH. Intracorneal asymmetrical rings for keratoconus: where should the thicker segment be implanted? *J Refract Surg* 2006; 22:307-309
11. Alió JL, Shabayek MH, Artola A. Intracorneal ring segments for keratoconus correction: long-term follow-up. *J Cataract Refract Surg* 2006; 32:978-985
12. Shabayek MH, Alió JL. Intrastromal corneal ring segment implantation by femtosecond laser for keratoconus correction. *Ophthalmology* 2007; 114:1643-1652
13. Siganos D, Ferrara P, Chatzinikolas K, Bessis N, Papastergiou G. Ferrara intrastromal corneal rings for the correction of keratoconus. *J Cataract Refract Surg* 2002; 28:1947-1951

14. Coskunseven E, Kymionis GD, Tsiklis NS, Atun S, Arslan E, Jankov MR, Pallikaris IG. One-year results of intrastromal corneal ring segment implantation (KeraRing) using femtosecond laser in patients with keratoconus. *Am J Ophthalmol* 2008; 145:775–779
15. Ertan A, Colin J. Intracorneal rings for keratoconus and keratectasia. *J Cataract Refract Surg* 2007; 33:1303–1314
16. Rodríguez LA, Guillén PB, Benavides MA, Garcia L, Porras D, Daqui-Garay RM. Penetrating keratoplasty versus intrastromal corneal ring segments to correct bilateral corneal ectasia: preliminary study. *J Cataract Refract Surg* 2007; 33:488–496
17. Busin M, Zambianchi L, Arffa RC. Microkeratome-assisted lamellar keratoplasty for the surgical treatment of keratoconus. *Ophthalmology* 2005; 112:987–997
18. Brierly SC, Izquierdo L Jr, Mannis MJ. Penetrating keratoplasty for keratoconus. *Cornea* 2000; 19:329–332
19. Bahar I, Kaiserman I, Srinivasan S, Ya-Ping J, Slomovic AR, Rootman DS. Comparison of three different techniques of corneal transplantation for keratoconus. *Am J Ophthalmol* 2008; 146:905–912
20. Watson SL, Ramsay A, Dart JKG, Bunce C, Craig E. Comparison of deep lamellar keratoplasty and penetrating keratoplasty in patients with keratoconus. *Ophthalmology* 2004; 111:1676–1682
21. Frost NA, Wu J, Lai TF, Coster DJ. A review of randomized controlled trials of penetrating keratoplasty techniques. *Ophthalmology* 2006; 113:942–949



First author:

Albert Daxer, MD, PhD

Eye Center, Linz-Ybbs, and Department of Ophthalmology, Medical University of Innsbruck, Innsbruck, Austria